

Nail Changes in Alopecia Areata and Their Correlation with Disease Severity

Hayder Raouf Al-Hamamy^{*}, Ghusoon Nazar Al-Ani^{**}

ABSTRACT:

BACKGROUND:

Alopecia areata (AA) is a chronic, autoimmune, inflammatory, non-scarring type of hair loss. Significant variations in the presentation of AA have been observed, ranging from small, well-circumscribed patches of hair loss to complete absence of body and scalp hair. Nail involvement is a common finding in patients with alopecia areata.

OBJECTIVE:

Study of nail changes in alopecia areata and evaluation of the correlation between the nail changes and severity of alopecia areata

PATIENTS AND METHODS:

The study is an observational, cross-sectional, descriptive study that was carried out at the Dermatology center, Medical City, Teaching Hospital, during the period from May 2018 to July 2019. The severity of (AA) was measured by the Severity of the Alopecia Tool Score1 (SALT1) score, in 70 patients with different severities of AA. A new measurement tool (Nail in Alopecia Areata Severity Index, NAASI score) was applied for the evaluation of the nail changes associated with AA.

RESULTS:

Seventy AA patients were divided into two groups, patients with nail changes, group A, which included 48 patients; 33 were males and 15 were females, the mean age was 19.19 ± 14.28 years. Group B included patients without nail changes; 22 patients; 11 were males and 11 were females, the mean age was 22.36 ± 11.50 years. NAASI score for patients in group A was 34 ± 31 . Pitting was the most common nail changes (38 patients), followed by trachyonychia, 15 patients. Group A was subdivided into two groups according to severity of AA. The mean NAASI score for the group with mild to moderate AA was 20 ± 23 , while it was 56 ± 28 for patients with severe AA. There was positive correlation between SALT1 and NAASI scores.

CONCLUSION:

The prevalence of nail changes in AA was 68.6%. They were associated with early onset and long duration of AA. Pitting was the most common changes. A new scoring system for nail changes was described. Nail changes correlated with severity of AA.

KEYWORD: Alopecia areata, Nails, SALT1, NAASI score.

INTRODUCTION:

Alopecia areata (AA) is a common, inflammatory, non-scarring type of hair loss. Significant variations in the clinical presentation of AA have been observed, ranging from small, well-circumscribed patches of hair loss to a complete absence of body and scalp hair.⁽¹⁾ Nail changes are a common feature of alopecia areata (AA) and are a significant source of cosmetic disfigurement and functional impairment. Nail changes may be

painful or cause problems with activities of daily living. Cosmetic disfigurement may be profound and has a significant impact on quality of life.⁽²⁾ The reported prevalence of nail changes ranges from 7% to 66%, with an average prevalence of approximately 30%.⁽³⁾ Some studies suggested that nail changes are more common in patients with more severe alopecia, such as alopecia areata universalis (AAU) and alopecia areata totalis (AAT).⁽³⁾ The most common nail changes reported in adults with AA are pitting (11.4–79.6%) and trachyonychia (8–14%).^(2,3)

^{*}Iraqi Board for Medical Specializations, Baghdad, Iraq.

^{**}Dermatology Center/ Medical City, Baghdad, Iraq .

NAIL CHANGES IN ALOPECIA AREATA

PATIENTS AND METHODS:

The study is an observational, cross-sectional, descriptive study. It was carried out at the Dermatology Centre, Medical City, Teaching Hospital, during the period from May 2018 to July 2019.

Patients with alopecia areata of scalp consulting the centre were included. Any patient who has connective tissue disease, psoriasis, lichen planus, congenital anomaly of nail or had used any kind of treatment for AA during the last six months was excluded from the study.

Formal consent was taken from each patient or their parents in case of children before starting the study, after full explanation about the study. The ethical approval was given by the Scientific Council of Dermatology and Venerology / the Iraqi Board for Medical Specializations.

A total number of 70 patients with alopecia areata were included in this study. Patients were divided into two groups: group A, included patients with nail changes, while group B, included patients without nail changes. Patients with alopecia areata and nail changes (group A) were subdivided, according to the SALT1 score, into mild to moderate disease ($\leq 50\%$) involvement and severe disease ($>50\%$) involvement.

The diagnosis of alopecia areata was established on clinical basis. Full history was taken from each patient regarding: age, age of onset and duration of disease type of AA, family history of similar conditions, any associated medical disease, history of previous attacks and current treatment for other diseases.

Thorough clinical examination of scalp was carried out including the following points: Type of AA, the number of lesions, sites, presence of exclamation mark hairs. The severity of AA was determined according to Olsen et. al⁽⁴⁾ with Severity of Alopecia Tool 1 (SALT 1) score.

Evaluation of the nail involvement was done by using Nail in Alopecia Areata Severity Index (NAASI score). In this score the nail is divided with imaginary horizontal and longitudinal lines into quadrants. Each nail is given a score (0-4) depending on the presence or absence of changes of nail in AA (including: pitting, trachyonychia, brittle nails, onychomadesis, onycholysis and koilonychias which are the most common reported nail changes in AA) in that quadrant. Then calculation of total scores of 20 nails was done (total 0 – 80 score).

Score of AA nails:

0 = none

1 = present in 1/4 nail

2 = present in 2/4 nail

3 = present in 3/4 nail

4 = present in 4/4 nail

Total for nail ____ (0 -4)

All patients were photographed with a mobile camera (HUAWEI Y6II,13MP) in the same illumination and distance.

SPSSv.25 (statistical package for social sciences version 25) was used for data input and analysis. Continuous variables presented as mean \pm SD (standard deviation) and discrete variables

presented as numbers and percentages. Chi square, T test and correlation coefficient were calculated.

RESULTS:

A total number of 70 patients with AA were included in this study. Patients were divided into two groups: group A, 48 patients (68.6%), included patients with nail changes, while group B,

NAIL CHANGES IN ALOPECIA AREATA

22 patients (31.4%), included patients without nail changes.

Table 1 shows characteristics of patients in the two groups. The duration of disease, number of lesions and SALT1 score were significantly higher in group A than group B. More patients in group A were younger than 18 years old.

The most commonly observed nail changes were pitting (figure 1) in 38 patients (54.2%) followed by trachyonychia (figure 2) in 15 patients (21.4%). The frequency of nail changes is demonstrated in figure 3.

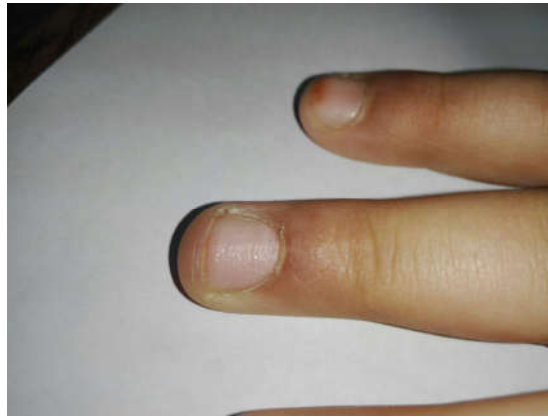

Figure 1: Pitting

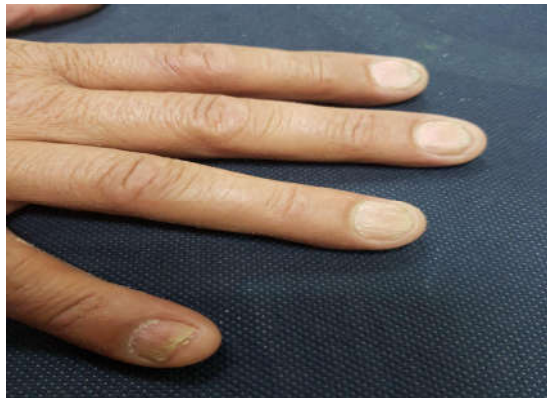

Figure 2: Trachyonychia

NAIL CHANGES IN ALOPECIA AREATA

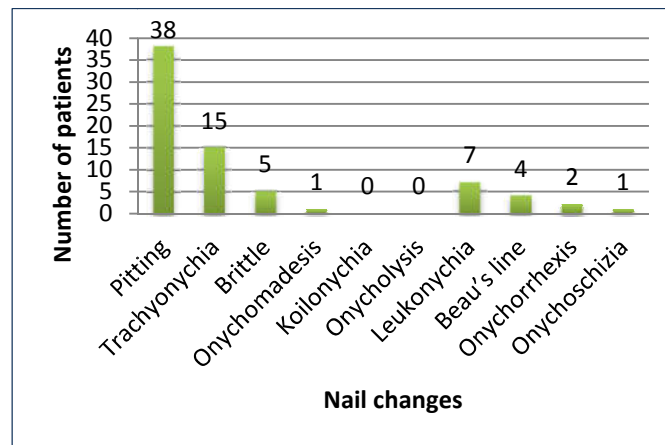


Figure 3: Frequency of nail signs in alopecia areata.

Regarding the site of nail involvement, only finger nails were involved in 23 patients (47.9%), toe nails only in 1 patient (2.1%), and both finger and toe nails involvement were observed in 24 patients (50%).

Patients with AA and nail changes (group A) were subdivided, according to the SALT1 score, into mild to moderate disease ($\leq 50\%$) included 29 patients (60.4%) and severe disease ($>50\%$) included 19 patients (39.6%).

The characteristics of two groups are shown in table 2. Patients with severe AA had significantly longer duration of the disease (P-value = 0.0007), and their NAASI score was significantly higher than patients with mild to moderate AA (P-value = 0.0001).

There was a significant correlation between disease severity measured with SALT1 and NAASI score, ($R^2 = 0.475$, P-value 0.00000006). Figure 4.

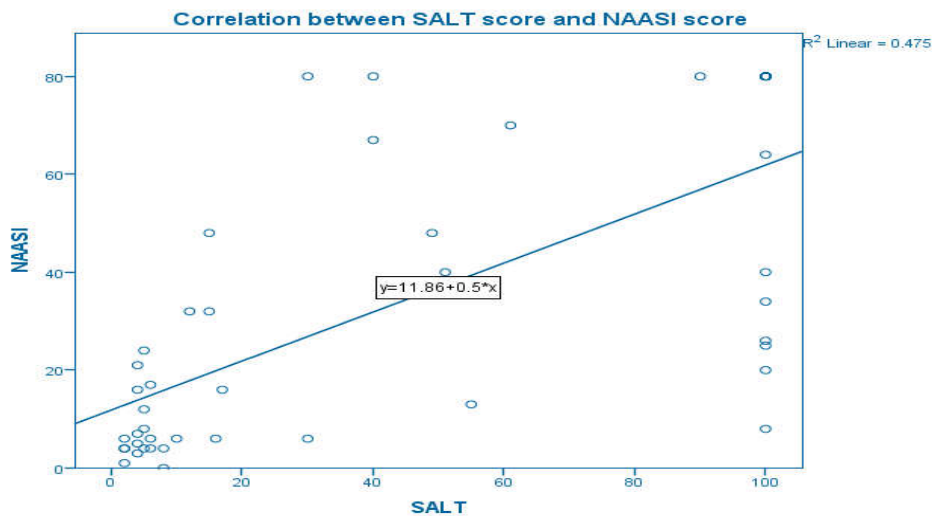


Figure 4: The correlation between NAASI and SALT1 score.

NAIL CHANGES IN ALOPECIA AREATA

Table 1. Characteristics of patients with alopecia areata in group A (with nail changes) and group B (without nail changes).

Characteristic	Group A (with nail changes) (n= 48 (68.6%))	Group B (without nail changes) (n= 22 (31.4%))	P-value
Gender			
Male	33 (68.8%)	11 (50%)	0.131
Female	15 (31.2%)	11 (50%)	
Age/years			
Mean \pm SD	19.19 \pm 14.28	22.36 \pm 11.50	0.364
Onset			
Childhood (<18 years)	35 (72.9%)	8 (36.4%)	0.003
Adulthood (>18 years)	13 (27.1%)	14 (63.6%)	
Duration/months			
Mean \pm SD	30.36 \pm 35.07	9 \pm 16.60	0.0084
Median	12	2.5	
Family history of AA	11 (22.9%)	6 (27.3%)	0.693
Types of AA			
Patches	26 (54.2%)	22 (100%)	-
Universalis	9 (18.8%)	0 (0%)	-
Totalis	7 (14.5%)	0 (0%)	-
Ophiasis	6 (12.5%)	0 (0%)	-
Associated diseases			
No	37 (77.08%)	16 (72.72%)	-
Atopy	8 (16.6%)	2 (9.09%)	-
Vitiligo	2 (4.16%)	2 (9.09%)	-
Down	1 (2.08%)	0 (0%)	-
Thyroid	0 (0%)	1 (4.54%)	-
No. of lesions			
Mean \pm SD	6.79 \pm 6.05	3.14 \pm 1.93	0.0075
SALT1 score			
Mean \pm SD	44.2 \pm 42	4.1 \pm 3	0.0001

NAIL CHANGES IN ALOPECIA AREATA

Table 2: Characteristics of patients with alopecia areata with nail changes (Group A), according to severity.

Characteristic	Mild to moderate (≤50% SALT1) (n= 29 (60.4%))	Severe (>50% SALT1) (n= 19 (39.6%))	P-value
Gender			
Male	18 (62.1%)	15 (78.9%)	0.217
Female	11 (37.9%)	4 (21.1%)	
Age/years			
Mean ± SD	18 ± 12	21 ± 17	0.4768
Onset			
Childhood (<18 years)	20 (69%)	15 (78.9%)	0.446
Adulthood (>18 years)	9 (31%)	4 (21.1%)	
Duration/months			
Mean ± SD	17.04 ± 26.30	50.68 ± 37.62	0.0007
Median	3	48	
Family history of AA	6 (31.6%)	5 (26.3%)	0.650
Types of AA			
Patches	26 (89.7%)	0 (0%)	-
Ophiasis	3 (10.3%)	3 (15.8%)	
Totalis	0 (0%)	7 (36.8%)	
Universalis	0 (0%)	9 (47.4%)	
Associated diseases			
No	22 (75.9%)	15 (78.9%)	-
Atopy	4 (13.8%)	4 (21.1%)	
Vitiligo	2 (6.9%)	0 (0%)	
Down	1 (3.4%)	0 (0%)	
NAASI score			
Mean ± SD	20 ± 23	56 ± 28	0.0001

DISCUSSION:

Nail changes in AA have been noted to precede, follow, and coincide with the onset of hair loss. ^(3,5) They are associated with more severe forms of AA in virtually all studies surveyed. ⁽³⁾ It is said that they indicate a poor prognosis. ⁽⁶⁾ In a study of 200 patients with alopecia areata; by kasumagic et al nail changes were observed in 25% of cases. ⁽³⁾ In children, studies suggested a prevalence rate of 30-46% according to Tosti et al ^(7,2) and Sharma et al. ⁽²⁾ Children are more likely to suffer from severe variants of AA, perhaps explaining the increased frequency of nail changes in this population. In one study, nail changes were more common in women with AA as compared to men, which was statistically significant (30% compared to 25.5%, P = 0.0257). ⁽⁸⁾ Trachyonychia in particular, however, was more common in males with AA. Studies comparing the prevalence of AA-associated nail changes across ethnic groups have not been reported. ⁽²⁾

In the present study, nail changes were observed in 68.6% of patients with Alopecia and there was no significant difference between males and females. Regarding the age of onset nail changes were observed in 72.9% of patients with alopecia areata of childhood onset compared with 27.1% of patients with adult onset, (P-value = 0.003). Regarding the severity of the disease in the present study the mean SALT1 for patients with nail changes was 44.2 while for patients without nail changes it was 4.1 (P-value = 0.0001). Nail involvement is more frequent among patients with severe AA, not only in this study, but also in other reports. ^(7,9, 10, 11, 6) Sharma et al. ⁽⁹⁾ reported a prevalence of nail dystrophy of 19.1% in all their patients, with a higher incidence of 49.4% in the severe forms of AA. while Garcia-Hernandez & Rodriguez-Pichardo ⁽¹⁰⁾ reported nail changes as a risk factor for developing severe forms of alopecia. In the study by Gandhi et al. ⁽¹¹⁾, none of the patients with AA patches type had nail changes.

NAIL CHANGES IN ALOPECIA AREATA

In the present study pitting was the most common nail finding. It was observed in 38 out of 70 patients with alopecia areata (54.2%). It was of the small regularly distributed pattern called the geometric pattern. Tosti et al⁽⁷⁾ and Kasumagis et al⁽³⁾ have reported pitting in one third to two thirds of their patients. In a study pitting was more common in the pediatric population than in adults. In AA, nail pits are classically shallow, with a grid-like distribution. This is in contrast to psoriasis, where pits are deep and randomly distributed.⁽²⁾

The second most common finding in the present study was trachyonychia. It was observed in 15 out of 70 patients with alopecia areata (21.4%). Trachyonychia was also described by Tosti et al⁽⁷⁾ and Kasumagis et al⁽³⁾. Trachyonychia was originally believed to be a hallmark feature of AA-associated nail changes. However, it is now thought that the presence of trachyonychia in a patient with AA does not exclude the possibility that this nail disorder may be because of a concomitant disease, such as lichen planus or psoriasis, or be idiopathic.⁽²⁾

Less specific nail changes such as leukonychia and Beau's lines were also observed in the present study in 7 patients and 4 patients, respectively. Van der Velden et al⁽¹²⁾ has shown that leukonychia is a nail feature that is not disease-specific, and is present in 65% of healthy subjects.

Interestingly, abnormalities of the toenails, without fingernail involvement, are less commonly seen.⁽²⁾ However, the number of nails affected varies by patient. One, several, or all nails may be involved. Twenty nails dystrophies with trachyonychia have been reported.⁽⁸⁾ In the present study, only one patient had toe nails involvement without finger nails involvement.

The pathogenesis of AA and its associated nail changes is incompletely understood. An interplay of genetic and immunological factors is associated with its onset and severity. Nail changes are more common with more severe variants of AA, such as alopecia areata universalis and alopecia areata totalis.⁽³⁾

On the molecular level, AA is thought to occur because of loss of immune privilege in the hair follicle. Normal hair follicles are normally an immune-protected site with lack of expression of major histocompatibility complex (MHC) class I and II and low numbers of dendritic antigen-presenting cells. It is thought that AA results from a lymphocytic infiltrate and expression of MHC I and II in the hair bulbs. The nail unit is also an

immune protected site. Nail changes in AA are likely associated with a lymphocytic infiltrate similar to that found in the hair bulbs of these patients. More research is needed to understand the pathophysiology of nail changes in AA.⁽²⁾

In one study, patients with AA-associated nail changes had lower levels of 25-hydroxyvitamin D levels compared to normal individuals.⁽¹³⁾ However, two other studies have shown no association.⁽¹⁴⁾

After careful search of literature, we did not find a study dealing with the scoring of nail changes in AA. In the present study a scoring system was applied, and was given the name of Nail in Alopecia Areata Severity Index (NAASI scoring), in this system each nail was divided with imaginary horizontal and longitudinal lines into quadrants. Each nail was given a score (0 - 4) depending on the presence or absence of any changes of nail in AA in that quadrant. Then calculation of total scores of 20 nails (total 0 - 80 score). This score is useful for determining severity of nail changes with AA. NAASI score showed a mean value of 20 ± 23 in patients with mild to moderate hair disease and 56 ± 28 in patients with severe AA (P-value 0.0001).

REFERENCES:

1. Strazzulla LC, Wang EHC, Avila L, et al. Alopecia areata: disease characteristics, clinical evaluation, and new perspectives on pathogenesis. *J Am Acad Dermatol*, 2018; 78:1-12.
2. Chelidze K, Lipner S. Nail changes in alopecia areata: an update and review. *Inter J Dermatol*, 2018;57:776-83.
3. Kasumagic-Halilovic E, Prohic A. Nail changes in alopecia areata: frequency and clinical presentation. *J Eur Acad Dermatol Venereol*, 2009; 23: 240-1.
4. Olsen EA, Hordinsky MK, Price VH, Roberts JL, Shapiro J, Canfield D, Duvic M, King LE, McMichael AJ, Randall VA, Turner ML. Alopecia areata investigational assessment guidelines-Part II. *J Am Acad Dermatol*, 2004;51:440-7.
5. Sakata S, Howard A, Tosti A, et al. Follow up of 12 patients with trachyonychia. *Australas J Dermatol*, 2006; 47: 166-8.
6. Ranawaka RR. An observational study of alopecia areata in Sri Lankan adult patients. *Ceylon Med J*, 2014; 59: 128-31.

NAIL CHANGES IN ALOPECIA AREATA

7. Tosti A, Morelli R, Bardazzi F, Peluso AM. Prevalence of nail abnormalities in children with alopecia areata. *Pediatr Dermatol*, 1994; 11: 112–5.
8. Lundin M, Chawa S, Sachdev A, et al. Gender differences in alopecia areata. *J Drugs Dermatol*, 2014; 13: 409–13.
9. Sharma VK, Dawn G, Muralidhar S, Kumar B. Nail changes in 1000 Indian patients with alopecia areata. *J Eur Acad Dermatol Venereol*, 1998; 10: 189–91.
10. Garcia-Hernandez MJ, Rodriguez-Pichardo A. Multivariate analysis in alopecia areata: risk factors and validity of clinical forms. *Arch Dermatol*, 1999; 135: 998–9.
11. Gandhi V, Baruah MC, Bhattacharaya SN. Nail changes in alopecia areata: incidence and pattern. *Indian J Dermatol Venereol Leprol*, 2003; 69: 114–5.
12. van der Velden HM, Klaassen KM, van de Kerkhof PC, Pasch MC. Fingernail psoriasis reconsidered: a case-control study. *J Am Acad Dermatol*, 2013; 69: 245–52.
13. Nassiri S, Saffarian Z, Younespour S. Association of Vitamin D level with alopecia areata. *Iran J Dermatol*, 2013; 16: 1–5.
14. Bakry OA, El Farargy SM, El Shafiee MK, et al. Serum Vitamin D in patients with alopecia areata. *Indian Dermatol Online J*, 2016; 7: 371.