

## Light Microscopic Study of the Effect of Zinc on Liver in Mice

Ahmed Anwar Albir

### ABSTRACT:

The study demonstrated that zinc affected the liver cells by giving the mice particular doses of zinc as  $ZnSO_4$ . The mice were divided into four groups of 6 mice each. Both of moderate and high dose groups showed various degrees of degenerative changes in the hepatocytes, such as increased size and the presence of spaces, dark appearance of the cytoplasm, whereas none of these changes were present in both group I (controls) and group II (low dose group).

### BACKGROUND:

According to previous studies, there is a correlation between certain doses of zinc and the changes that may occur in the liver cells.

### METHODS:

The study was conducted on mice, which were divided into four groups of six mice each. Group I received tap water during the entire period of experimentation (30 days), group II, group III and group IV were received 5 mg, 10 mg and 15 mg/Kg body weight zinc as  $ZnSO_4$  consecutively (orally and daily). Sections of livers were made and examined by light microscope.

### RESULTS:

Zinc affected liver cells (hepatocytes) in mice under certain doses. Group III and group IV animals which received 10 mg and 15 mg/kg body weight zinc as  $ZnSO_4$  consecutively showed various degrees of degenerative changes in the hepatocytes, such as increased size and the presence of spaces, dark appearance of the cytoplasm. The degree of these changes was more abundant in liver cells of high dose group in comparison with the changes in liver cells of moderate dose group, whereas none of these changes were present in both group I (controls) and group II (low dose group) which received tap water and 5mg/kg body weight zinc consecutively.

### CONCLUSION:

Certain doses of zinc could cause damages to the liver cells.

**KEY WORDS:** Zinc, Liver, Mice.

### INTRODUCTION:

Zinc (Zn) belongs to trace elements, which play an important role in the growth and development of the organism. The mechanism of its activity is based on the participation of this microelement in the structure of the macro molecular compounds and in the activation of many enzymes. Zinc enzymes take part in the synthesis and decomposition of proteins, fats, carbohydrates and nucleic acids. Zinc also plays an essential part in the gene expression: it stabilises the DNA and RNA structure and influences their synthesis whereby it controls the replication and transcription. Zn also participates in hormone regulation, influencing hormone synthesis and secretion as well as modulating peripheral hormone activity. At the same time, many hormones control the level and distribution of Zn in the organism. Besides, zinc is a component of the peroxide dismutase-an antioxidative enzyme that takes part in the elimination of free radicals<sup>3</sup>. Zinc has been identified as a central component of over 300 enzymes involved in metabolism and cells, and it

Plays an essential structural function in an entire class of transcription factors<sup>4</sup>. Zinc has been shown to inhibit apoptotic DNA fragmentation and caspase-3 activity, implicating involvement in both nuclear and cytoplasmic compartments.

Furthermore, studies have shown that zinc inhibits the activation of caspase-3 by suppressing the cleavage of pro-caspase-3. These studies together suggest that zinc would interfere with both upstream and downstream events of caspase-3 activation<sup>5</sup>. Zinc is crucial for normal embryonic development of vertebrates, fulfilling a variety of functions including transcription, translation, and cell proliferation. Chelatable zinc is present in significant concentrations in the postnatal CNS, particularly in relation to forebrain glutamatergic systems. Similarly, other organs in which histochemically-reactive zinc has been reported include pancreatic islets and the seminiferous tubules of the testis<sup>6</sup>. Metallothioneins (MTs) are low - molecular weight, cysteine - rich proteins<sup>1, 7,10,12,13</sup>. They may play a role in the intracellular storage of zinc<sup>7</sup>. MT has a more prominent role in inflammation-mediated tissue Zn redistribution<sup>8</sup>.

University of Baghdad, College of Dentistry.

The coordination between zinc and MT is that MT retains high levels of zinc in the liver under physiological conditions and releases zinc under oxidative stress conditions, leading to potent antioxidant action<sup>13</sup>.

On the other hand, chronic cadmium (Cd) exposure can cause renal proximal tubular dysfunction resulting from the release of Cd metallothionein (CdMT) from the liver and its accumulation and degradation in the renal tubular epithelial cells. Pretreatment with zinc can protect against acute CdMT nephrotoxicity<sup>11</sup>.

#### **MATERIAL AND METHODS:**

Twenty four adult male of Swiss white mice (aged 75 days each) were divided into four groups (6 mice each). The animals in group I were used as controls and given only tap water during the entire period of experimentation (30 days), group II animals were given 5 mg /Kg body weight zinc as Znso<sub>4</sub> orally and daily (considered as low dose group), group III animals were given 10 mg/Kg body weight zinc (Considered as moderate dose group) and group IV animals were given 15 mg/Kg body weight zinc (considered as high dose group).

At the end of the period, two animals from each group were selected and anesthetized with chloroform; the livers were removed consecutively and fixed immediately in 10% formalin overnight. The livers were dehydrated in alcohol, then placed in xylene to remove alcohol and embedded in paraffin wax. The embedded livers in paraffin were sectioned by a microtome.

As described elsewhere by Ratcliffe<sup>9</sup>, the sections were stained by using hematoxylin and eosin procedure. A drop of Canada balsam was placed on each section and covered with a cover slip and allowed to dry.

The sections were prepared for examination by light microscope. Photographs were made at low and high magnification.

#### **RESULTS:**

This work was conducted on mice, which were divided into four groups of six mice each.

The examination of the paraffin sections of the livers of both group I (controls) and group II (low dose group) showed no particular changes in the hepatocytes of the liver as in Figs (1, 2, 3 and 4), whereas the sections of the livers of both group III (moderate dose group) and group IV (high dose group) showed various degrees of degenerative changes in the hepatocytes, such as increased size and the presence of spaces, dark appearance of the cytoplasm. The degree of these changes was more abundant in liver cells of high dose group in comparison with the changes in liver cells of moderate dose group, as in Figs (5, 6, 7 and 8).

#### **DISCUSSION:**

As mentioned in the results, the examination of the sections of the livers of both group III (moderate dose group) and group IV (high dose group) which received 10 mg and 15 mg/kg body weight zinc as Znso<sub>4</sub> consecutively showed various changes in the hepatocytes such as increased size and the presence of spaces, dark appearance of the cytoplasm. These changes were more abundant in liver cells of high dose group in comparison with the changes in liver cells of moderate dose group (Figs 5 , 6 , 7 and 8), whereas none of these changes were present in both group I (controls) and group II (low dose group) which received tap water and 5 mg/kg body weight zinc consecutively .

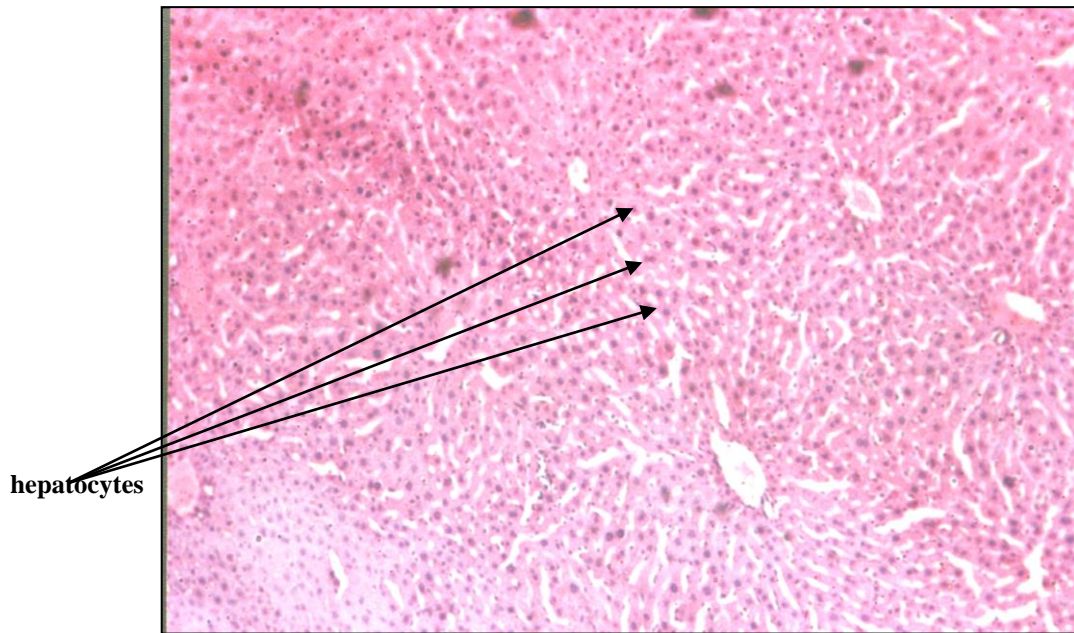
It could be said that group III and group IV received doses of zinc which caused histopathological changes. That coincides largely with the notion of Florianczyk<sup>3</sup>.

That a change in zinc content in the tissues can be observed in many pathological processes .

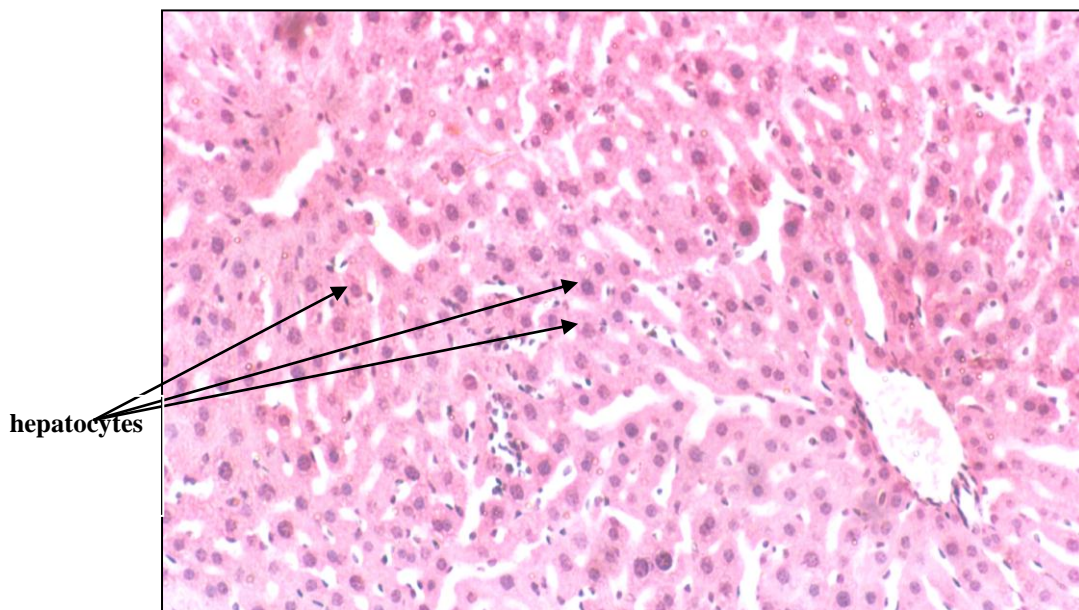
Damek-Poprawa<sup>2</sup> mentioned that zinc is an essential metal physiologically, but it may also alter the function of organisms when the exposure dose exceeds a critical threshold.

#### **CONCLUSION:**

This study demonstrated that under certain doses of zinc, it is possible to cause changes that affected the structure of the liver cells.

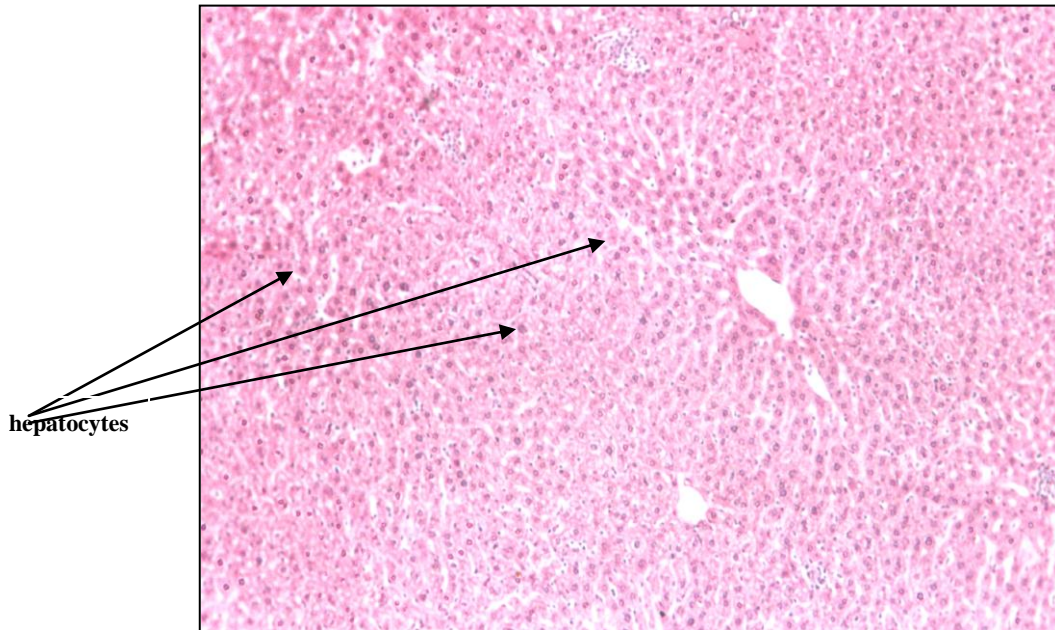


**Fig. 1**  
**40X**  
**Transverse Section of Liver Lobule (hepatocytes)**  
**in Mice (Control group)**

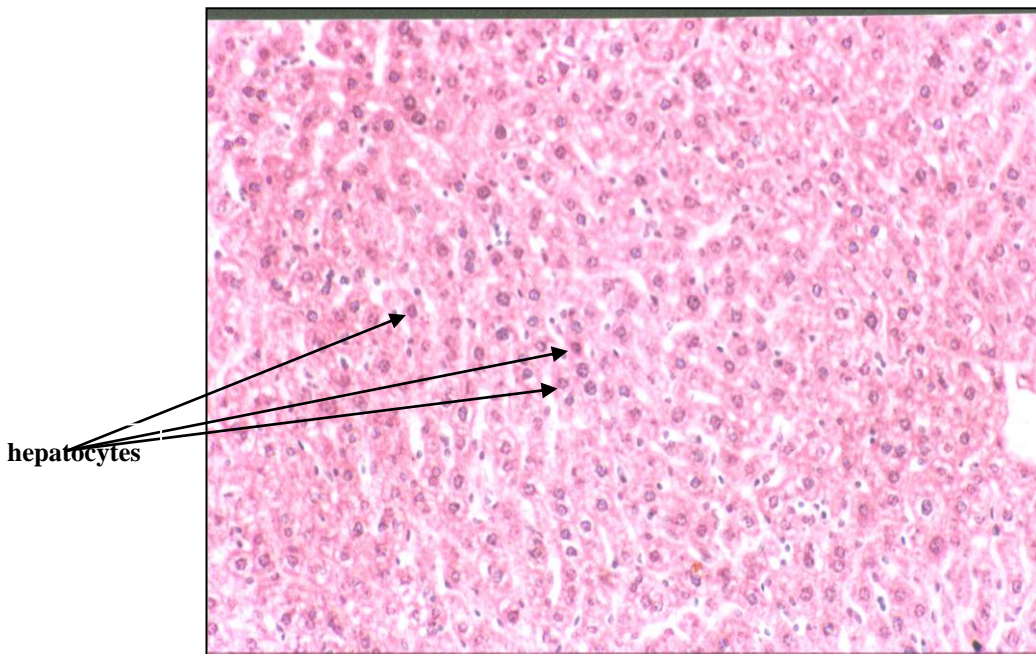


**Fig. 2**  
**400X**  
**Transverse Section of Liver Lobule ( hepatocytes) in Mice**  
**Showing no particular changes in the hepatocytes (Control group)**  
**Stain: Hematoxylin and Eosin**

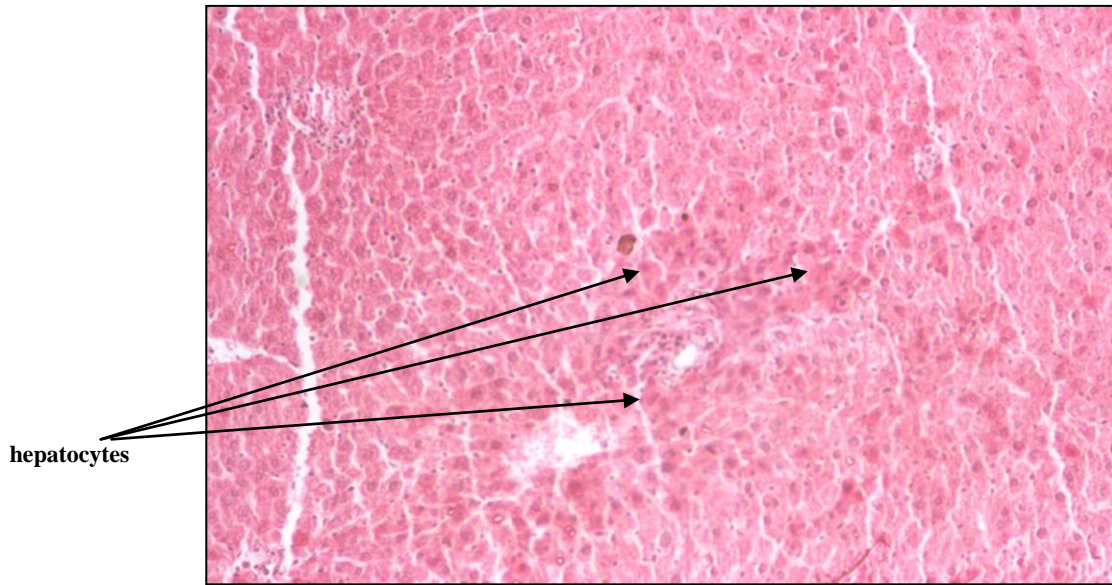




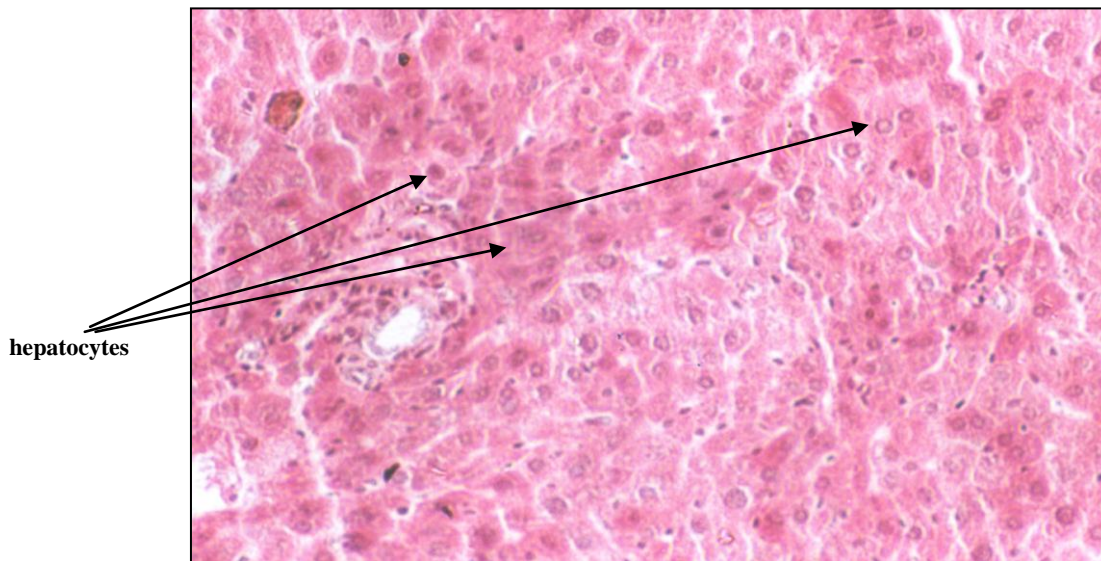
**Fig. 3**  
40X  
Transverse Section of Liver Lobule (hepatocytes)  
in Mice (Low dose group)



**Fig. 4**  
100X  
Transverse Section of Liver Lobule ( hepatocytes) in Mice  
Showing no particular changes in the hepatocytes (Low dose group)  
Stain: Hematoxylin and Eosin

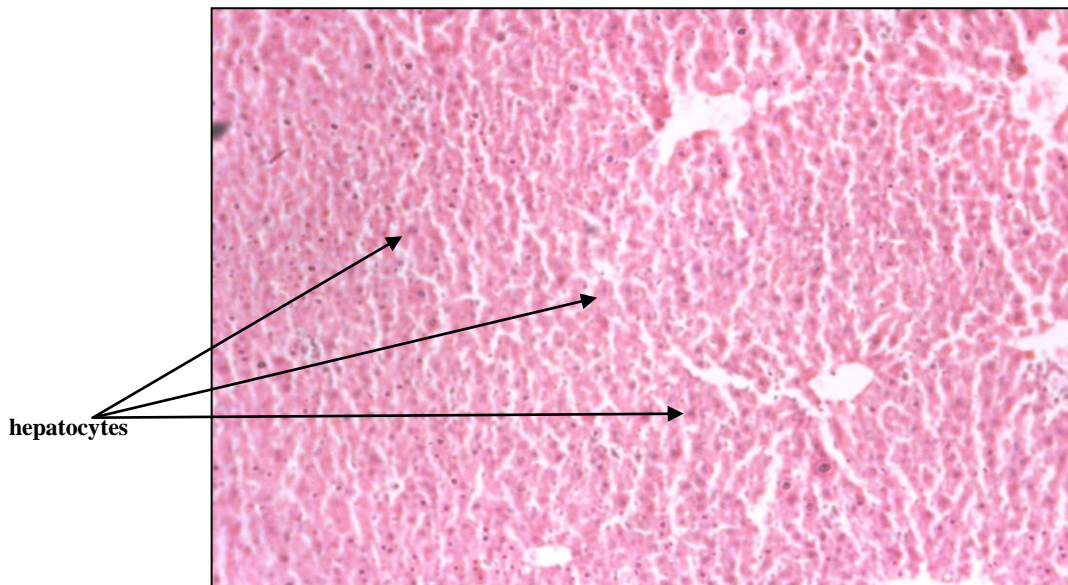


**Fig. 5**  
**100X**  
**Transverse Section of Liver Lobule (hepatocytes)**  
**in Mice (Moderate dose group)**

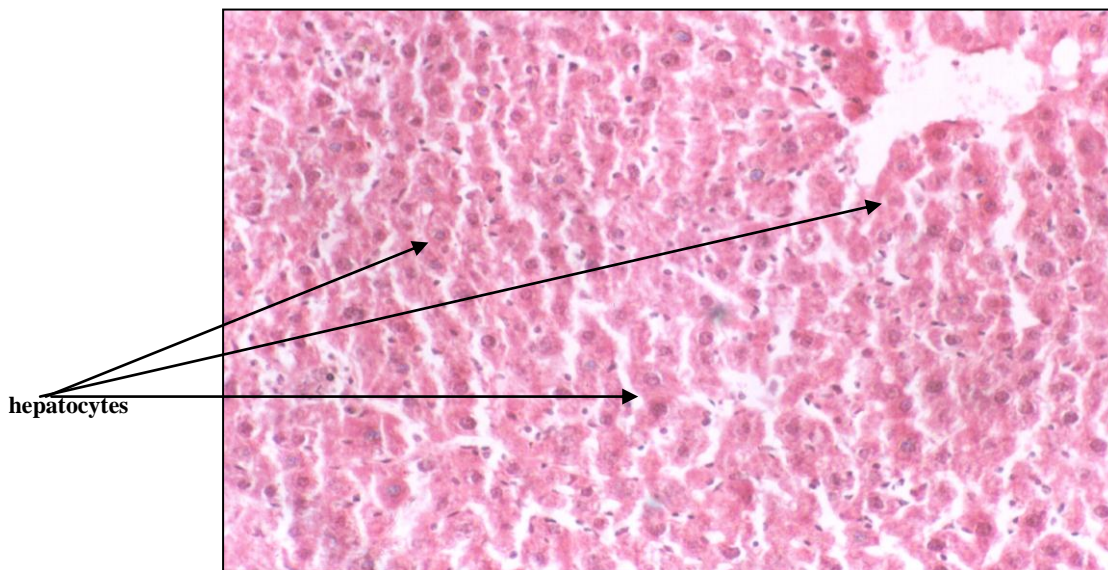


**Fig. 6**  
**400X**  
**Transverse Section of Liver Lobule ( hepatocytes) in Mice**  
**Showing abundant changes in the hepatocytes, such as increased size**  
**and the presence of spaces, dark appearance of the cytoplasm.**  
**(Moderate dose group)**  
**Stain: Hematoxylin and Eosin**





**Fig. V**  
**100X**  
**Transverse Section of Liver Lobule (hepatocytes)**  
**in Mice (High dose group)**



**Fig. ^**  
**400X**  
**Transverse Section of Liver Lobule ( hepatocytes) in Mice**  
**Showing more abundant changes in the hepatocytes, such as increased size**  
**and the presence of spaces, dark appearance of the cytoplasm.**  
**(High dose group)**  
**Stain: Hematoxylin and Eosin**

## REFERENCES:

1. Davis, Steven R.; Robert J. McMahon and Robert J. Cousins (1998) : Metallothionein knockout and transgenic mice exhibit altered intestinal processing of zinc with uniform zinc-dependent zinc . *J. Nutr.* 128, 825-831 .
2. Damek-Poprawa, Monika and Katarzyna Sawicka-Kapusta (2003) : Damage to the liver, kidney, and testis with reference to burden of heavy metals in yellow-necked mice from areas around steelworks and zinc smelters in Poland . *Toxicology* . 186, 1-10 .
3. Florianczyk, Bolestaw (2000) : Zinc level in selected tissues of ethanol and morphine intoxicated mice. *Med Sci Monit* . 6,680-683.
4. Kondoh, M.; N.Imada; K. Kamada; R.Tsukahara; M.Higashimoto; M. Takiguchi; Y.Watanabe and M. Sato(2003) : Property of metallothionein as a Zn pool differs depending on the induced condition of metallothionein. *Toxicology Letters*. 142, 11-18.
5. Lambert, Jason C.; Zhanxiang Zhou and Y.James Kang (2003) : Suppression of Fas-mediated signaling pathway is involved liver apoptosis. *Exp.Biol. Med.* 228, 406-412 .
6. Nitzan, Yuval B.; Israel Sekler and William F.Silverman (2004) : Histochemical and histofluorescence tracing of chelatable zinc in the developing mouse . *J.Histochem. Cytochem.* 52, 529-539 .
7. Oliver, Jordan R.; Tom W.Mara and M.George Cherian (2005) : Impaired hepatic regeneration in metallothionein-I/II knockout mice after partial hepatectomy . *Exp . Biol . Med* . 230, 61-67 .
8. Philcox, Jeffrey C.; Marieke Sturkenboom; Peter Coyle and Allan M. Rofe (2000) : Metallothionein in mice reduces intestinal zinc loss during acute endotoxin inflammation, but not during starvation or dietary zinc restriction . *J.Nutr.* 130, 1901-1909 .
9. Ratcliffe, N.A(1982). *Practical Illustrated Histology* . 2. some useful hints and recipes for the preparation and examination of stained histological sections .
10. Rofe,A.M.; E.F.Barry;T.L.Shelton;J.C.Philcox and P.Coyle (1998) : Paracetamol hepatotoxicity in metallothionein-null mice. *Toxicology*. 125, 131-140 .
11. Tang, Weifeng; Selma Sadovic and Zahir A.Shaikh (1998) : Nephrotoxicity of cadmium-metallothionein : protection by zinc and role of glutathione . *Toxicol. Appl . Pharmacol* . 151,276-282 .
12. Wang, Ying; Ursula Wimmer; Peter Lichtlen ; Daniel Inderbitzin ; Bruno Stteger ; Peter J.Meier ; Lukas Hunziker ; Thomas Stallmach ; Rhea Forrer ; Thomas Rulicke ; Oleg Georgiev and Walter Schaffner (2004) : Metal-responsive transcription factor-1 (MTF-1) is essential for embryonic liver development and heavy metal detoxification in the adult liver. *FASEB J.* 18, 1071-1079 .
13. Zhou, Zhanxiang;Xiuhva Sun; Jason C.Lambert ; Jack T.Saari and Y.James Kang (2002) : Metallothionein-independent zinc protection from alcoholic liver injury . *Am.J.Pathol* . 160, 2267-2274.