

Value of Fine Needle Aspiration Cytology Under Ultra-Sound Guided Biopsy in the Diagnosis of Prostatic Cancer

Usama S.Al-Nasiri*, Adil H Hamoodi **, Raghil J Hameed ***

ABSTRACT:

BACKGROUND:

The detection of carcinoma of prostate (CaP) by trans rectal ultrasound (TRUS) depends on the feature produced by the new growth, which leads to changes in the glandular—stromal architecture, appears as changes in the echogenicity of the prostatic lesion. The fine needle can be guided to the area of suspicion and cytology is done.

OBJECTIVE:

This prospective study was conducted to demonstrate the usefulness of the fine needle aspiration cytology (FNAC) under transrectal ultrasound (TRUS) guidance in detection of carcinoma of the prostate (CaP).

METHOD AND PATIENTS:

Fifty male patients aged between (46 - 86) years, were chosen selectively, all with voiding symptoms & suspicion of CaP from an elevated prostate specific antigen (PSA) above the level of 4 ng/ml in all patients. Thirty patients had abnormal finding on digital rectal examination (DRE), thirty three patients had TRUS abnormal findings. This procedure was carried out on an out-patient basis. The cytological results were compared with the tissue diagnoses obtained by surgical interventions.

RESULTS:

The cytological results revealed 24 cases of malignancy & benign in the rest 26 cases (23 cases of BPH & 3 cases of prostatitis). Malignancy was correctly diagnosed by using cytology in 24 out of 28 cases confirmed by histopathology as CaP. One case was considered initially as false positive, the cytological result consistent with adenocarcinoma but the histopathology failed to prove it.

The statistical analysis revealed that the sensitivity, specificity and accuracy were 85%, 100% & 92% respectively.

CONCLUSION:

We conclude that FNAC under TRUS guidance can be considered as an initial safe cost effective & reliable method for diagnosing of Prostate cancer.

KEY WORD: prostate, FNA, TRUS, PSA, cytology.

INTRODUCTION:

The clinical application of TRUS began by Watanabe in 1968, using B-Mode transducers to detect size and shape of the prostate but not the internal echo⁽¹⁻³⁾. In 1981 Saitoh et al & Holm et al working separately developed special TRUS intervention unit for needle guidance to puncture the prostate & seminal vesicles^(3,4). This improvement in visualization of the internal structures of the prostate was corresponding to Mc

Neal 1981 concept of zonal anatomy of the prostate. This concept replaced the concept of lobular structure of prostate⁽⁵⁾.

According to Mc Neal concept of zonal anatomy the prostate has been divided by the urethra into anterior fibromuscular portion (non-glandular) & posterior (glandular) portion^(5,6,7) & each zone makes contact with specific portion of the urethra. The development and maintenance of the prostate occurs through androgen-dependent tissue⁽⁸⁾.

Gray-scale TRUS has become the most common imaging modality for the prostate. Most commonly used for prostate cancer detection⁽⁹⁾. The combination of PSA & DRE is more sensitive than

*Professor and Consultant in Urology, Medical City Complex.

Departement of urology, Alshaheed Ghazi Alhariri for Surgical Specialty

Medical

** Head of Urology Department, Medical City Complex.

***Specialist at Urology Department, Medical City Complex.

TRUS alone in CaP detection & once suspected CaP, should be confirmed by prostatic biopsy^(6,7,10).

Lee & CO. workers in 1986 clearly demonstrated that the most common appearance of CaP is a hypoechoic peripheral zone lesion⁽²⁾ but this is not specific for CaP. About (20- 40 %) of CaP is isoechoic echotexture & (10%) of CaP is hyperechoic echotexture⁽¹¹⁾. The smallest tumor lesion of the prostate, which can be detected by TRUS, is 4.4 mm in maximum⁽¹²⁾. ultrasound guidance offers a new tool to revitalize and redefine the role of the interventional cytopathologist⁽¹³⁾.

PSA is a glycoprotein⁽¹⁴⁾, considered as one the most clinically useful tumor marker for the screening & early detection & follow up of patients with CaP^(15,16,17). At present, the data suggests that a cut off point of 4ng/ml. PSA elevation is not specific for CaP⁽¹⁸⁾ but occur in the setting of other Prostatic diseases (e.g. BPH, prostatitis), as well as prostatic manipulations (e.g. prostatic massage, prostatic biopsy). However not all men with Prostatic carcinoma have elevated PSA level⁽¹⁹⁾ and (25 %) of CaP of PSA level below 4ng /ml⁽⁸⁾.

The fine needle aspiration (FNA) is a safe & accurate diagnostic procedure. It has been widely applied in the diagnosis of lesion of various organs (lymph node, stomach, breast and kidney)^(20,21).

The cytology diagnostic discipline has arisen in parallel with the histopathology. It subserves both a screening and predictive function. Unfortunately, in many instances, these two streams in pathology developed as essentially separate disciplines so that the interchange of new ideas to the benefit of both did not occur as readily as it should have⁽²²⁾.

The FNA of lesions suspected of malignancy on DRE is equally sensitive & specific to core needle biopsy and clearly a valuable diagnostic modality. A large needle biopsy, though as accurate as FNA, gives rise to significantly more complications⁽¹⁶⁾. In patient without outflow obstruction, FNA is the least invasive method of diagnosing CaP⁽²²⁾.

When histological confirmation of prostatic carcinoma is required in elderly patients, transrectal prostatic FNA is a valid alternative to transrectal biopsy, due to its excellent. The aim of the study is to evaluate the diagnostic yield of this technique in patients with voiding symptoms & suspicion of prostatic cancer.

PATIENTS AND METHODS:

This prospective study was carried out from December 2009 to October 2013 at the Medical City

a total of 50 male patients were chosen selectively; Their ages ranged between (46-86) years. All of them complain of different voiding symptoms & suspicion of CaP. The PSA levels of those patients were elevated above 4ng/ ml; twenty four patients of them ranges between 4-10 ng/ml. & the rest (26) patients were above 10ng/ml. Thirty patients had abnormal DRE findings (hard nodule or nodular surface)

Each patient was informed first about the procedure of TRUS & FNA. The preparations for such procedure included, cleansing enema done at morning of the examination; A prophylactic oral antibiotics are essential started at the day before examination & continued for one week later plus a single intramuscular dose of gentamycin (80mg) one hour before the examination.

The transducer was prepared by placing the guide over the probe inserted slowly & gently into the rectum & an axial scan was obtained first, starting from the base towards the apex of the prostate.

The suspicious area was identified & localized by the axial scan & through this area a sagittal scan obtained, then fine needle (23 gauge, 200mm length with stylet) was introduced through the guide till its tip reached the suspicious area, then the stylet removed & a negative pressure was created by 20cc syringe, with the needle moving back & forth within the lesion along the same track, then the negative pressure released before drawing the needle out from the gland to avoid the escape of the aspirated material into the syringe and also to avoid the contamination of the aspirate with the rectal contents.

The aspirate smeared on dry, alcohol-cleaned slides & fixed immediately in 95% alcohol. Then these slides stained with hematoxylin & eosin [H & E]. Another 3-4 samples taken from different zonal areas. The cytological result compared with histopathological sample. A standard matrix analysis was performed to determine the test operating characteristics which include, sensitivity, specificity & accuracy.

The formula used in calculation:

Sensitivity = (No. of true positive / No. of diseased patients) x 100

Specificity = (No. of true negative / No. of diseased patients) x 100

Accuracy = ((No. of true positive + No. of true negative) / Total sample) x 100

RESULTS:

A total no of 50 male patients with voiding

FINE NEEDLE CYTOLOGY IN DIAGNOSIS OF PROSTATIC CANCER

symptoms with suspicion of CaP from an elevated PSA >4ng/ml. twenty four patients (48%) had a range between (4-10 ng/ml.) & the rest(26) patients (52 %) had a level above 10ng/ml. Thirty patients (60 %) had abnormal findings on DRE (hard nodule or nodular surface). While thirty three patients (66 %) had abnormal findings on TRUS.

The cytological results revealed 24 case of malignancy & benign in the rest 26 case (23 case of BPH & 3 cases of prostatitis).

Malignancy was correctly diagnosed by using cytology in 24 out of 28 case confirmed by histopathology as CaP. All of them were consistent with adenocarcinoma of the prostate .BPH was

confirmed histologically in 16 out of 19 cases. Prostatitis was diagnosed in 3 cases by cytology & histopathology.

Only three cases needed second aspirate of the prostate because the first aspirate was inconclusive (two of them showed cellular atypia & one was hypocellular).

One case was considered initially as false positive, the cytological result was consistent t with adenocarcinoma but the histopathology failed to prove it; later this patient proved to have adenocarcinoma of the prostate by follow up core biopsy. The statistical analysis (table I) revealed that the sensitivity, specificity and accuracy were 85%. 100% & 92% respectively.

Table 1: Calculation of sensitivity, specificity and accuracy.

		Prostate cancer	
		positive	negative
Test outcome	positive	24	0
	negative	4	22

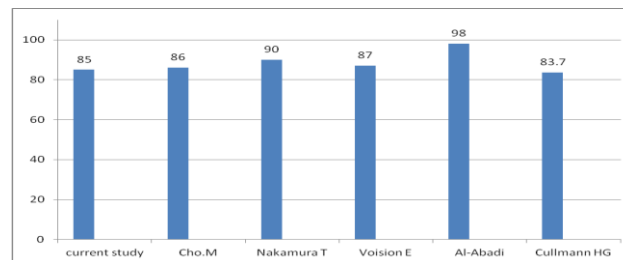


Figure I :Comparison of the sensitivity.

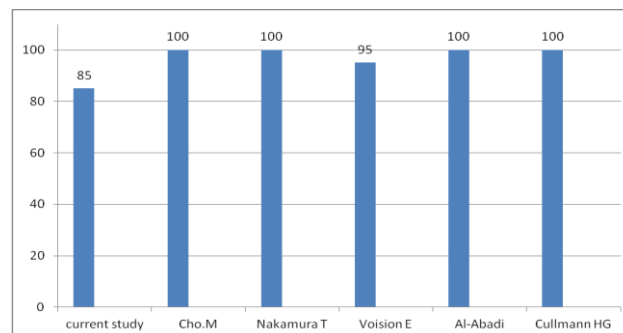


Figure II : Comparison of the specificity.

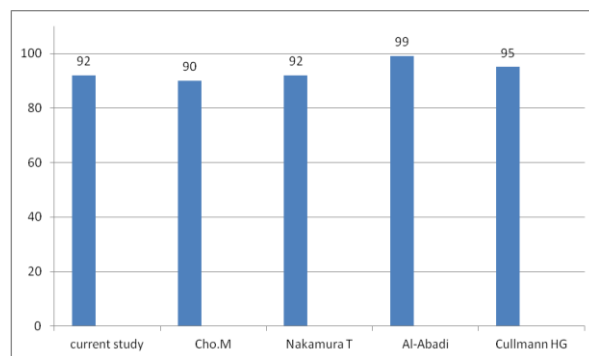


Figure III : Comparison of the accuracy

DISCUSSION:

CaP is the commonest human cancer in the world it is commonly found in men at age of 50 ,(30 %)of autopsy in the 6th decade of life⁽⁷⁾. It is the most common diagnosed and is the second leading cause of cancer death in American men⁽²⁴⁾. While in the United Kingdom it is the 6th most common neoplasm⁽¹⁰⁾. In Iraq, it is registered to be one of the commonest 10 cancers in male⁽²⁵⁾.

FNAC under TRUS guidance can sample small prostatic lesions as well as any anatomical area (e.g. trapezoid area, transitional zone& peripheral zone) accurately & can also sample the entire needle pathway in the prostate. The cytological results can be obtained within one hour, which is one of the important characteristics of this procedure .The cytological findings must interpreted accurately by an expert cytologist. The sensitivity of FNAC in our study was 85% which is less than that of Clio.M . 86%⁽²⁹⁾ , Nakamura T. 90%⁽²⁶⁾ Voi sin -E. 87%⁽²⁷⁾& Al-abadi-H. 98%⁽²⁸⁾ & higher than that obtained by Cullmann HJ.83.7%⁽³⁰⁾ (figure I). The specificity was 100% which is similar to that of Clio. M⁽²⁹⁾ , Nakamiira-T⁽²⁶⁾, Al-abadi-H⁽²⁸⁾ & Cullmann HJ⁽³⁰⁾ & higher than that of Voisin-E. 9S %⁽²⁷⁾. (figure II). The accuracy rate was 92% in our study, which is similar to that reported by Nakainiira-T. & less than that of Cullmann HJ 95% & of Al-Abadi H ' 99% & higher than that of Cho. 90%.(figure III).

Cho. M. reported a rate of 11 % of false negative⁽²⁹⁾ while no case of false negative was reported in our study .

Only three patients^(6%) need second aspirate because of inadequacy of the aspirate for diagnosis(one patient as hypocellular & two patients as cellular atypia), which was less than that reported by Cho-M. 13%⁽²⁹⁾ & higher than that of Al-abadi —H. 2.8%⁽²⁸⁾ and Ibrahim 3.44%⁽³¹⁾.

The cytological result of one patient in this study initially regarded as false positive, which was

reported later as an early detection of CaP. It was also reported in the study done in Iraq in 1995 by M. Noori& R. A.Fadhil (32).Ekman et al were able to confirm cancer histologically in 6 out of 7cases with an initial unsupported cytological diagnosis of malignancy by repeated surgical biopsies up to 3 years later⁽²²⁾. Radge et al considered the patient has prostatic adenocarcinoma if either the biopsy or the cytological aspiration were positive for cancer⁽³³⁾.

Only minor discomfort was recorded regarding the introduction of the rectal probe by 60% of cases ,the FNAC by transrectal route is easiest, accurate, quick method, with minimal discomfort⁽³⁴⁾. With the use of the regime of antibiotics & enema, the infection rate was recorded in 2%. No major complications were recorded.

The aspiration easily is performed repeatedly in the cases of inconclusive cytology.

CONCLUSION:

FNAC of the prostate is a Safe , accurate cost effective easy repeatability & least invasive method for the diagnosis of prostatic carcinoma. It should be considered as a reasonable initial diagnostic procedure for detection prostatic cancer.

The high number of correct diagnoses, low false positive rate underline the great accuracy of this method. The FNAC of the prostate is not a substitute for conventional surgical histopathology , it should be regarded as an extremely valuable complement to it , to improve early detection of prostatic cancer.

REFERENCES:

1. Resnick M. Transrectal ultrasonography in the detection & staging of prostatic cancer. World G. Urol 1989;7: 2-6.
2. Edouard J. Trabulsi, Ethan J. Halpern, Leonard G. Gomella, Ultrasonography of the prostate & biopsy. Campbell-Walsh Urology 10th ed. Philadelphia, WB Saunders;2012:27-35.

3. Watanabe H. History & application of transrectal sonography of the prostate. *Urol Clin North Am* 1989;16:617-22.
4. Holm H, & Garmelgaard J. Ultrasonically guided precise needle placement in the prostate & the seminal vesicles. *J. URL* 1981 vol.125 March :358-586.
5. Lee F, Torp P-ST, Siders DB et al. Trans rectal ultrasound in the diagnosis & staging of prostatic carcinoma. *Radiology* 1989; 140:609-615.
6. Ronald G. Grainger, David Allison (ed.). Grainger & Allison's diagnostic radiology: A textbook of Medical Imaging.4th ed. Churchill Livingstone 2001:1438-51.
7. Diane M, Kawamura . Diagnostic medical sonography, Abdomen& superficial structure,2nd 1 ed. Philadelphia , Lipincott-Raren, 1997:447-77.
8. David M. Berman, Ronald Rodriguez, Robert W. Veltri. Development, Molecular Biology, and Physiology of the Prostate. *Campbell-Walsh Urology* 10th ed. Philadelphia, WB Saunders;2012:2540.
9. Edouard J. Trabulsi,Ethan J. Halpern, Leonard G. Gomella, Ultrasonography and Biopsy of the Prostate:Campbell-Walsh Urology 10th ed. Philadelphia, WB Saunders;2012:2737
10. Redman J . Anatomy of the genitourinary system, In: Gillen water Gray hack J, Howards S etal (ed.). *Adult & Pediatric Urology*,1st ed. Chicago, Year book Medical publishers 1987:143-44.
11. Weisleder R, Reinmount MJ Wittenberg J.Primer of diagnostic imaging 2nd ed. St.louis,MoSby year book,Inc 1997:298-301.
12. Shinohara K.Scardino P. Carter S.& Wheeler . Normal and malignant prostate. *Urologic clinic of north America* 1989 vol 16,No 4:675-91.
13. Lieu D.Cytopathologist-performed ultrasound-guided fine-needle aspiration and core-needle biopsy: a prospective study of 500 consecutive cases.*Diagn Cytopathol.* 2008; 36:317-24.
14. Otis W Brawley,prostate cancer screening,Emerging Cancer Therapeutics, Demos Medical Publishing, 2011;2:455.
15. Potosk A.L M iller B.A,Albertsen P.C,et al.The role of increasing detection in the rising incidence of prostate cancer .*JAMA* 1995;273:548-52.
16. Osterling J .E.Prostate specific antigen. Making an excellent tumor marker even better .*Prostate cancer communicator* 1996;1:67.
17. Kilnchi E,Nakashima .J,Ishibashi,et al Prostate specific antigen adjusted for transition zone volume. The most powerful method for detecting prostate carcinoma .*American Cancer Society* 2000.Cancer 2000;89:842-48.
18. H. Ballentine Carter, Stacy Loeb. Early Detection, Diagnosis, and Staging of Prostate Cancer. *Campbell's Urology*,10th ed. WB Saunders 2012:2763.
19. Devita V.T, Hellman S, Rosenberg S.A.Cancer principles & practice of oncology 5th ed, Lippincott-Raven publishers 2012;vol.2: I322-77.
20. Raji H. Al-Hadithi, Zinah M.A, Kaali, Usama N. Rifat, Sabaah Al-Kadi, Riyadh Abd Al-sattar.Role of fine needle aspiration cytology in diagnosis of prostatic lesions. *IRAQI MEDICAL JOURNAL* 1994,1995,1996;43,44,-45:1-5.
21. Fiobert L. Schmidt, MD, PhD, MBA, Kirsten Howard, PhD, Brian J. Hall, MD, Lester J. Layfield, MD. Comparative Effectiveness of Fine-needle Aspiration Cytology Sampling Policies .*Am J Clin Pathol.* 2012;138:823-30.
22. Manual and Atlas of Fine Needle Aspiration Cytology. Male & Female genital organ, Clinical aspects. 1987;182-91.
23. Planelles Gómez J, Beltrán Armada JM, Alonso Hernández S.Value of transrectal FNA in the diagnosis of prostate cancer in elderly patients,*Actas Urol Esp.* 2008;32:485-91.
24. Joseph C Presti. Neoplasm of the prostate gland. *Smith's general urology* 17th ed. Mc Graw Hill 2007:399-418.
25. Fornage BD. Normal ultrasound anatomy of the prostate. *Ultrasound Med Biol* 1986;12:1011-21.
26. Nakamura-T; Akimoto-S; Shimazaki-J. Usefulness of fine needle aspiration cytology in the diagnosis prostatic cancer.*Hinyokika-Gakki-Zasshi.* 1995; 86: 853-59.
27. Voisin-E; Piaton-E; Duco-F; Morettini-C; Brocard-MC; Toscan-Du-Plantier-N. Systemic bilateral aspiration biopsy in the screening of prostatic cancer. *J-Urol-paris.* 1999;96:343-47.
28. Al-Abidi-H. Fine needle aspiration biopsy vs. ultrasound-guided transrectal random core biopsy of the prostate . Comparative investigations in 246 cases., *Acta-Cytol.* 1997; 41: 981-86.

29. Ch-M ; Shimizu-K; Okajima—E; Yamada-H; Fukui; Tami-Y; Hirata-N; Maruyama-Y. Fine needle aspiration cytology in Screening for Prostatic cancer. *Hinyokika-Kiyo* 1995; 41: 365-68.
30. Tariqul Islam, Tamanna Chowdhury, KH Khan. Fine Needle Aspiration Cytology of Prostatic Lesions with Histologic Correlation, *Ibrahim Med. Coll. J.* 2007;1:7-10.
31. Cullman-HJ. Current value of transrectal fine needle biopsy .High predictive value in the diagnosis of prostate carcinoma 1991.
32. M. Noori & Riyadh A. Fadhil. A comparative study of ultrasound guided transrectal FNAC & biopsy of the prostate. A thesis subjected to the Iraqi Commission For Medical Specialization. 1995.
33. Radge H. , Aldape H. & Bagley C. Ultrasound guided prostate biopsy. *Urology*, 1988;32:503-8.
34. Chayanika Pantola, Sanjay Kala, P.K.Singh. A Correlative Study Between Transrectal FNAC And Histology Of The Prostate For The Detection of Prostate Carcinoma, *Journal of Dental and Medical Sciences (IOSR.JDMS)* Volume 1, Issue 12012:18-20.